




**CONCORSO PUBBLICO PER TITOLI ED ESAMI PER LA COPERTURA DI N° 1 POSTO DI:  
DIRIGENTE MEDICO OFTALMOLOGIA**

**PROVA PRATICA N.1**

**OCT - PUCKER.**





PROVA N° 1  
26/13/23



BA

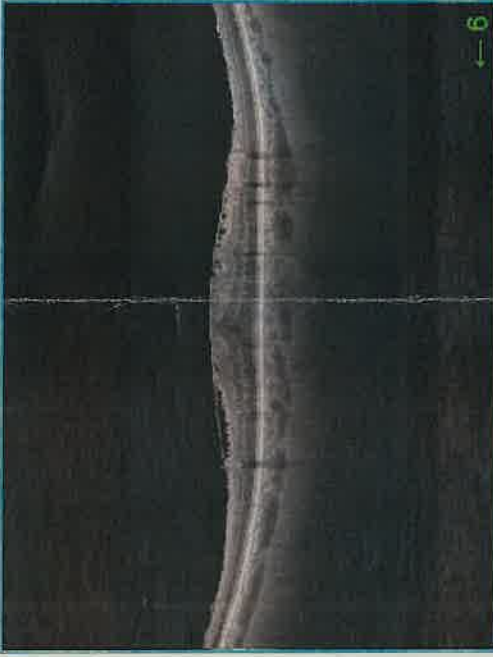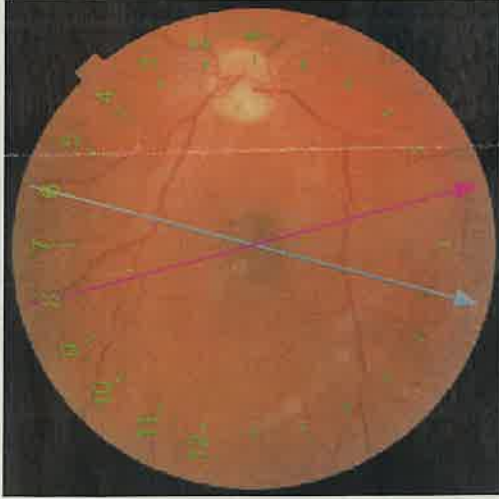
# TOPCON Radial Report

ID:   
 Name:   
 Technician: Triton  
 Fixation: Macula  
 Scan: Radial(12.0mm - 1024x12)

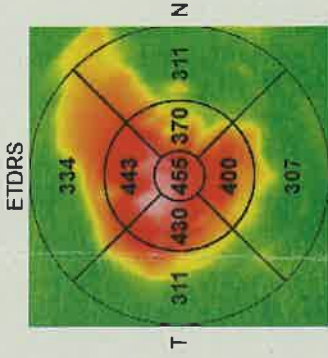
Ethnicity: Caucasian  
 Gender: Male  
 DOB: 17/11/1966 Age: 56

Image Quality: **98** Analysis mode: Fine (2.0.7)  
 Capture Date: 20/03/2023

**OD(R)**

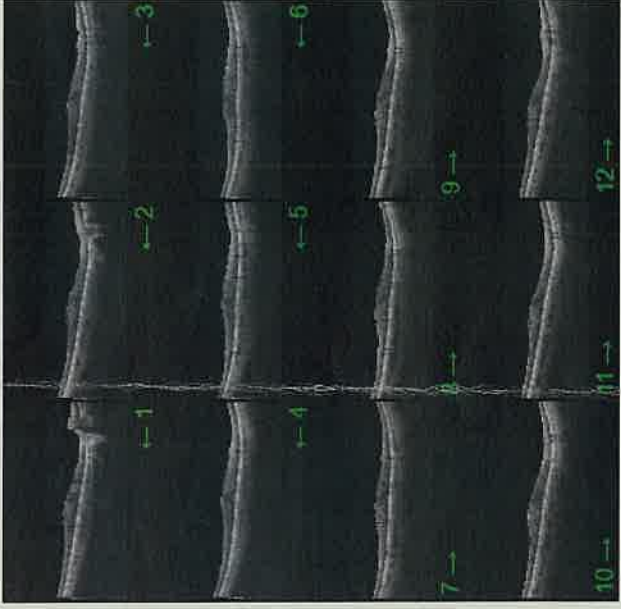
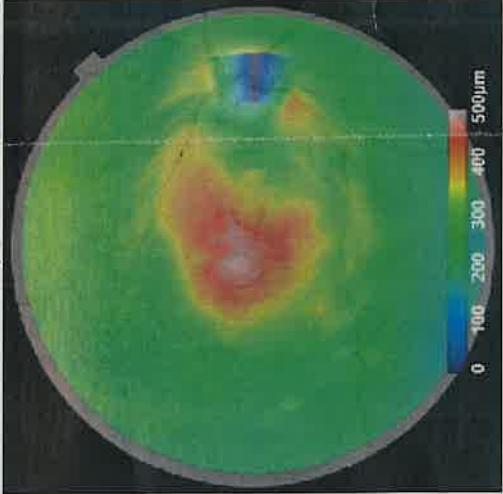


Retinal thickness ILM-OS/RPE(µm)



Average Thickness (µm) **340.7**

Retinal thickness map ILM-O/S/RPE / Red-free



Comments:

Signature:

Date:

**CONCORSO PUBBLICO PER TITOLI ED ESAMI PER LA COPERTURA DI N° 1 POSTO DI:  
DIRIGENTE MEDICO OFTALMOLOGIA**

PROVA PRATICA N. 2

FAG - RETINOPATIA DIABETICA.

The image shows three distinct handwritten signatures or scribbles in black ink. The one on the left is a large, looped signature. The one in the upper right is a long, sweeping signature. The one in the lower right is a shorter, more angular signature.

Prima prova pratica  
26/01/23

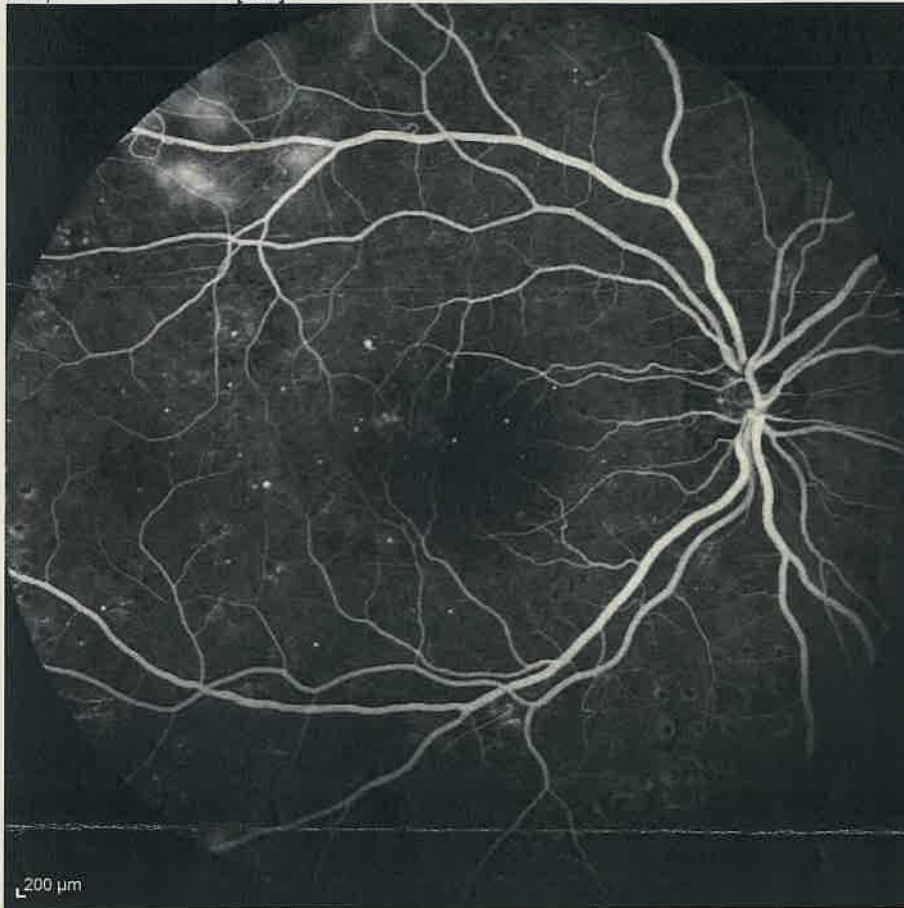
M. M.

58

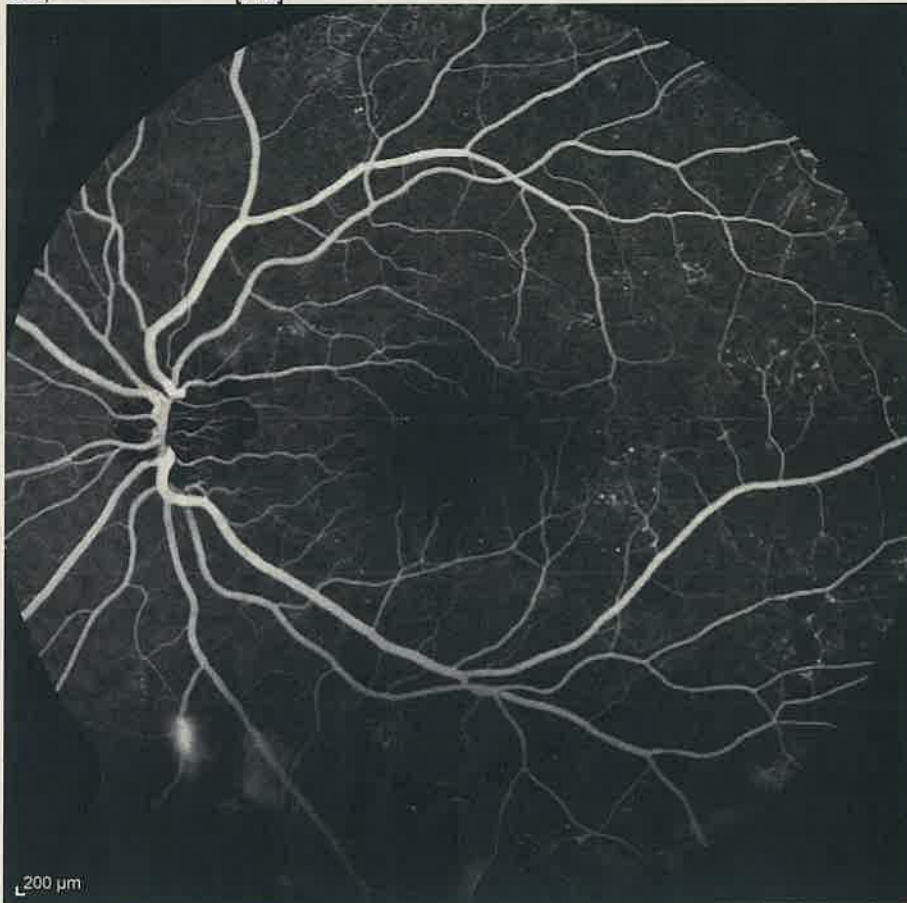
Patient: ██████████  
Patient ID: ---  
Diagnosis: ---

DOB: 16/mar/1994      Sex: F  
Exam.: 12/dic/2022  
Comment: ---

OD, FA 1:06.96 55° [HS]



OS, FA 0:55.73 55° [HS]





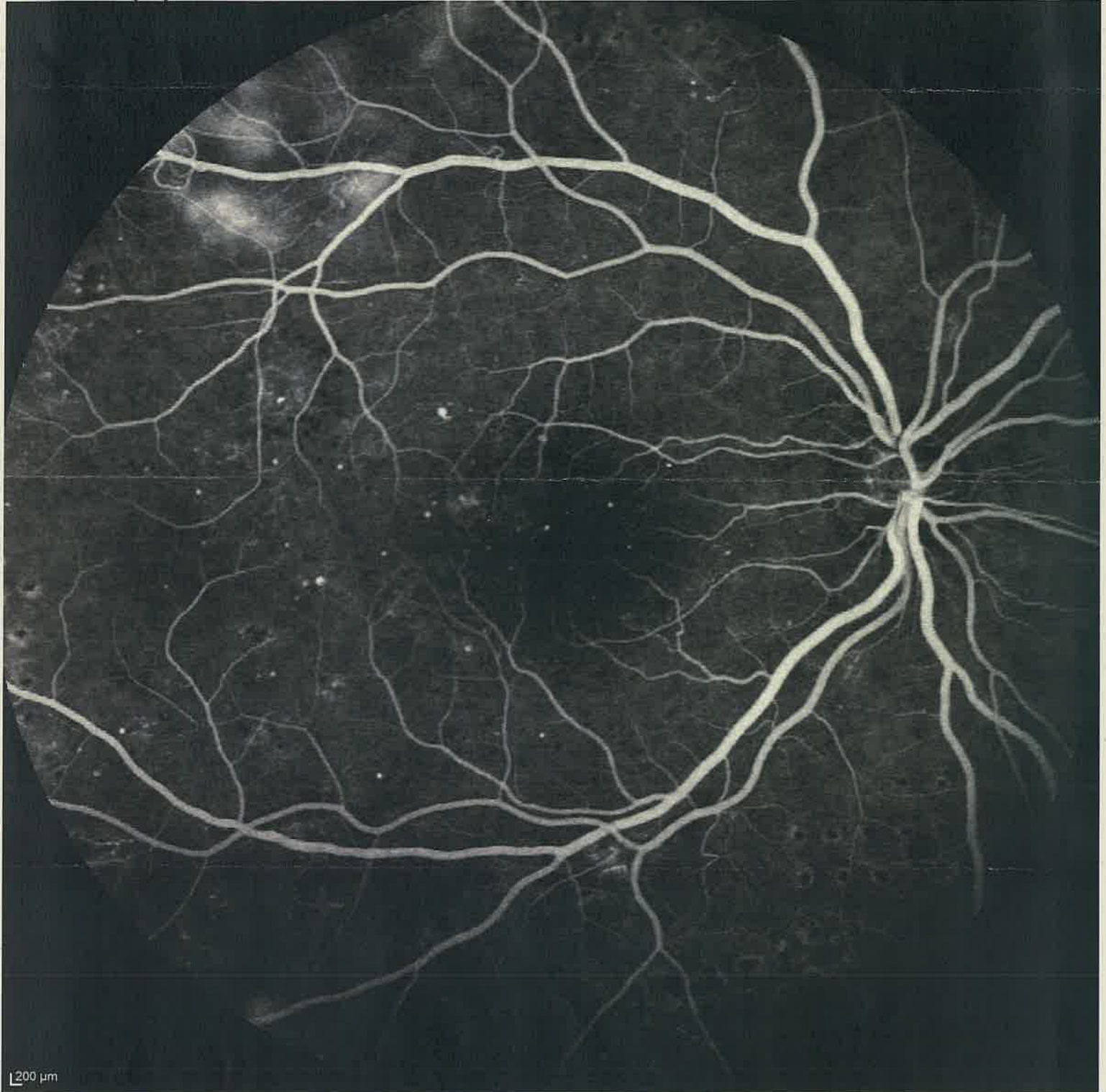
Patient: ██████████  
Patient ID: ---  
Diagnosis: ---

DOB: 16/mar/1994  
Exam.: 12/dic/2022  
Comment: ---

Sex: F

OD

FA 1:06.96 55° [HS]



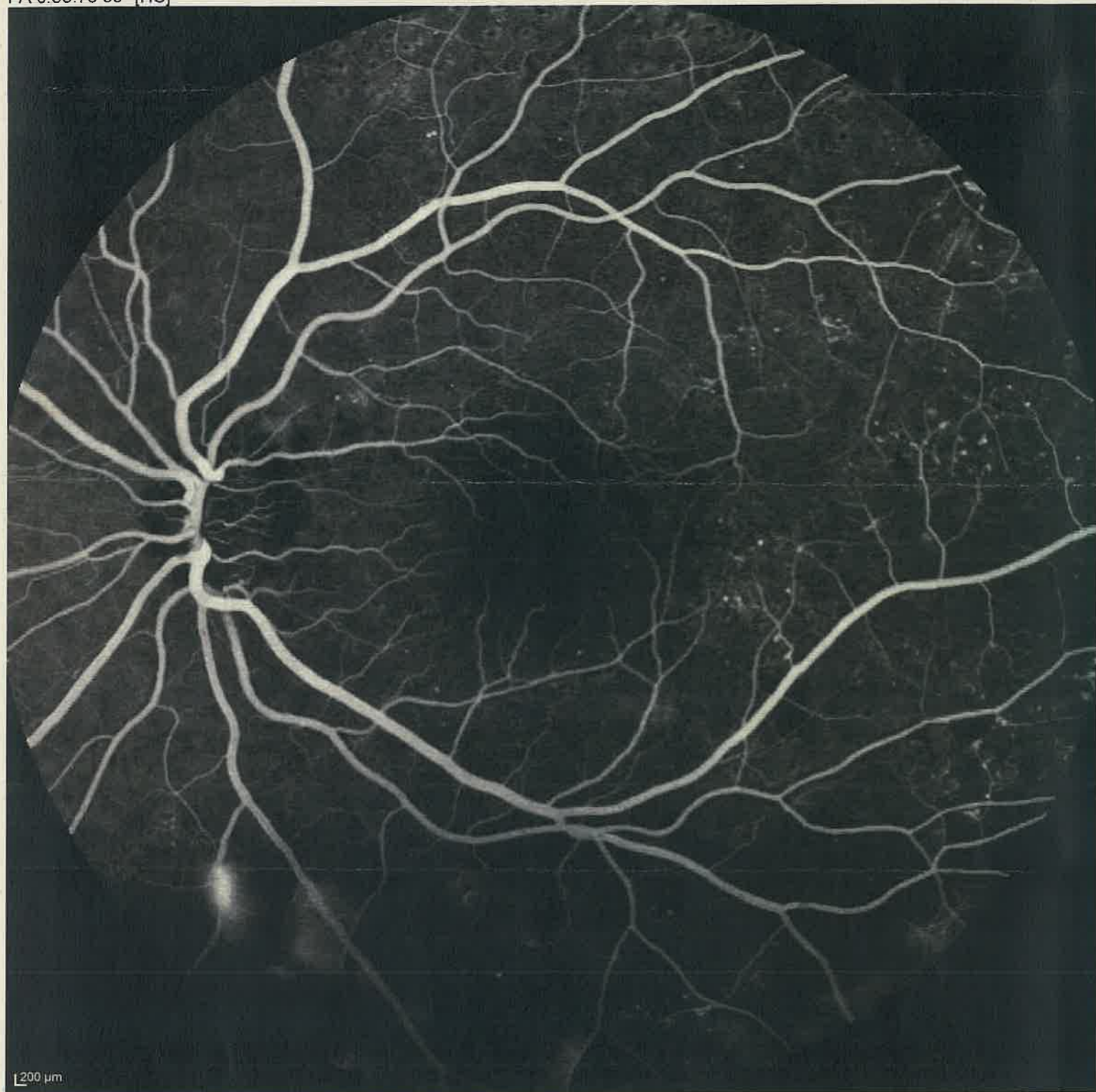
Patient: ██████████  
Patient ID: ---  
Diagnosis: ---

DOB: 16/mar/1994  
Exam.: 12/dic/2022  
Comment: ---

Sex: F

**OS**

FA 0:55.73 55° [HS]





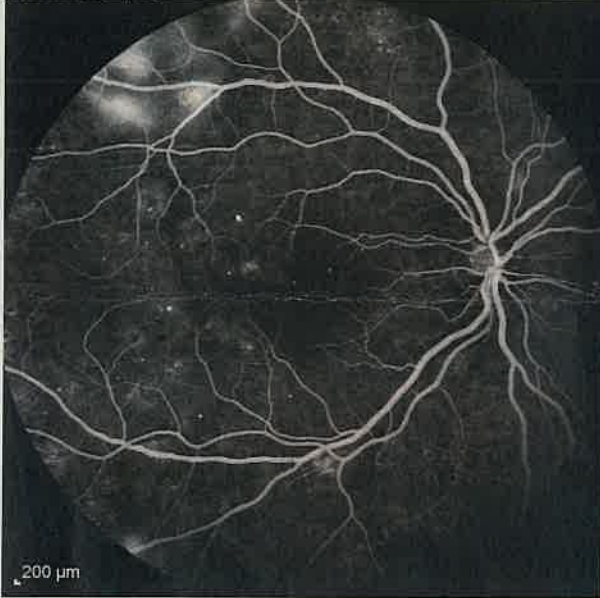
Patient: **ASL AL - Anni alisa**  
Patient ID: ---  
Diagnosis: ---

DOB: 16/mar/1994  
Exam.: 12/dic/2022  
Comment: ---

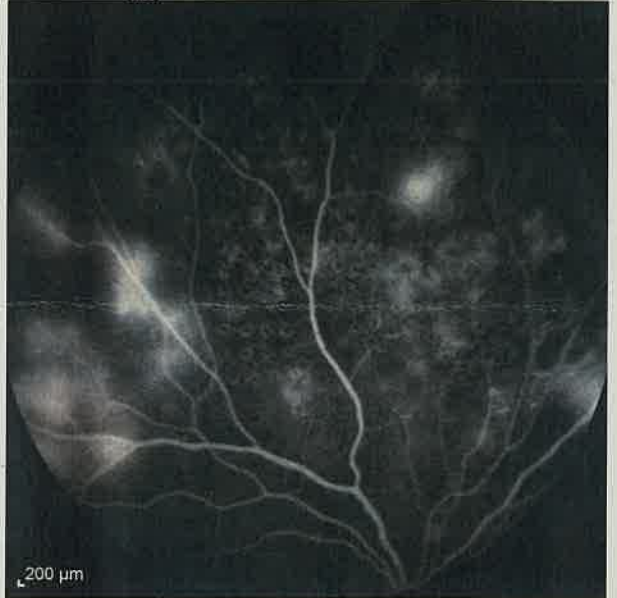Sex: F

**OD**

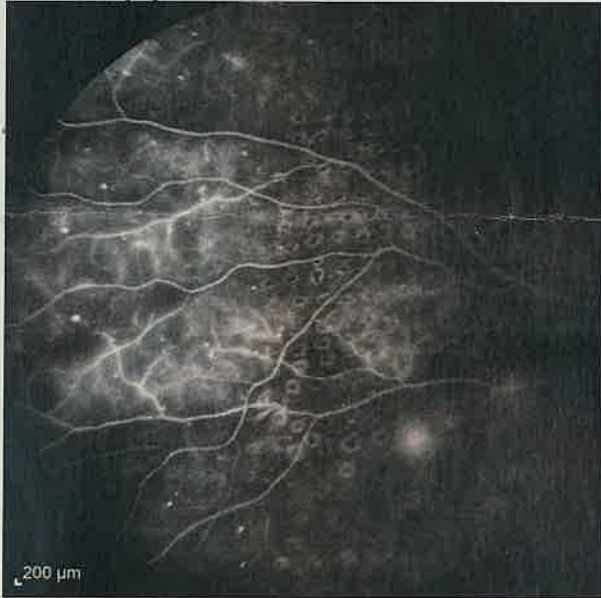FA 1:57.45 55° [HS]



FA 3:42.28 55° [HS]



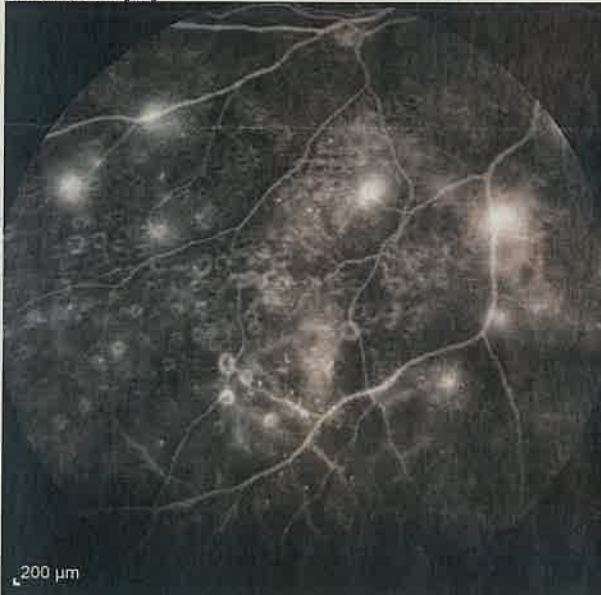FA 3:56.58 55° [HS]



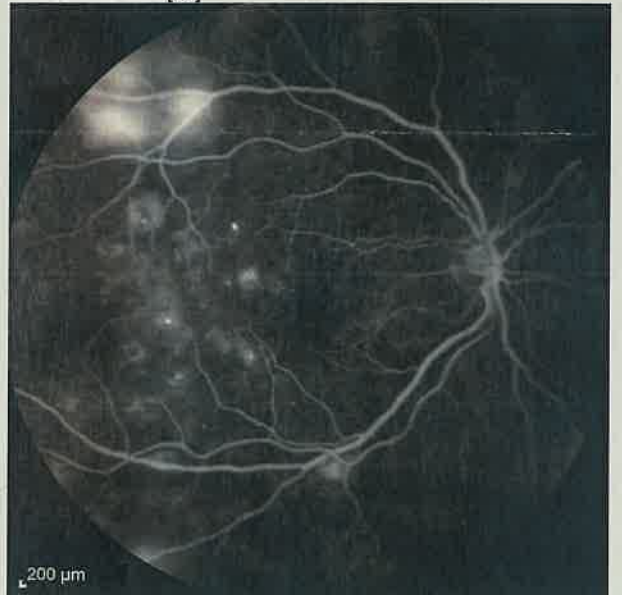FA 4:05.20 55° [HS]



FA 4:17.00 55° [HS]



FA 4:33.46 55° ART [HS]



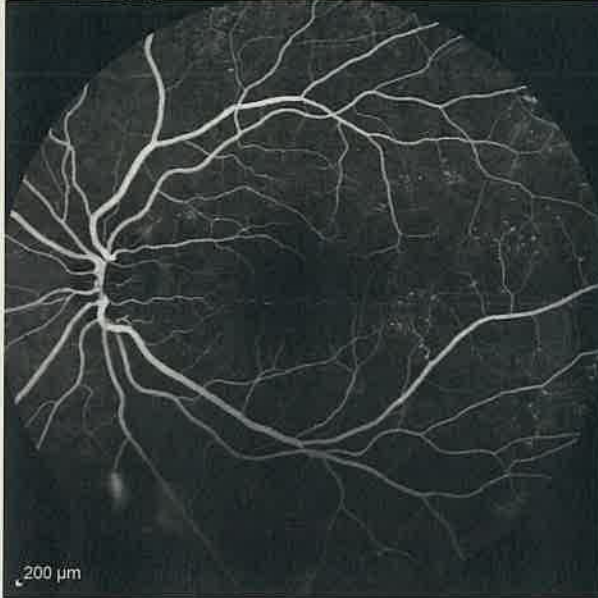
Patient: **[REDACTED]**  
Patient ID: ---  
Diagnosis: ---

DOB: 16/mar/1994  
Exam.: 12/dic/2022  
Comment: ---

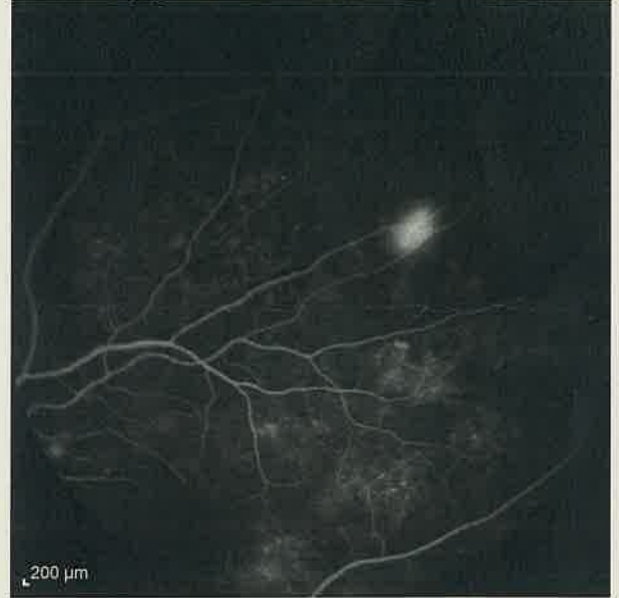Sex: F

**OS**

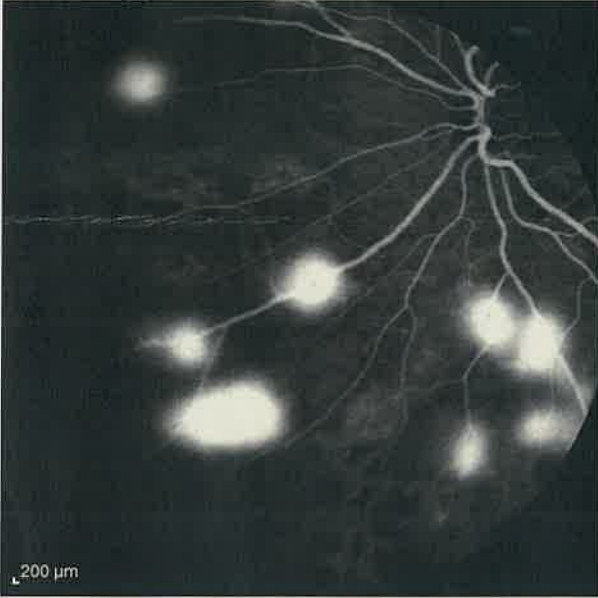
FA 0:53.91 55° [HS]



FA 2:39.77 55° [HS]



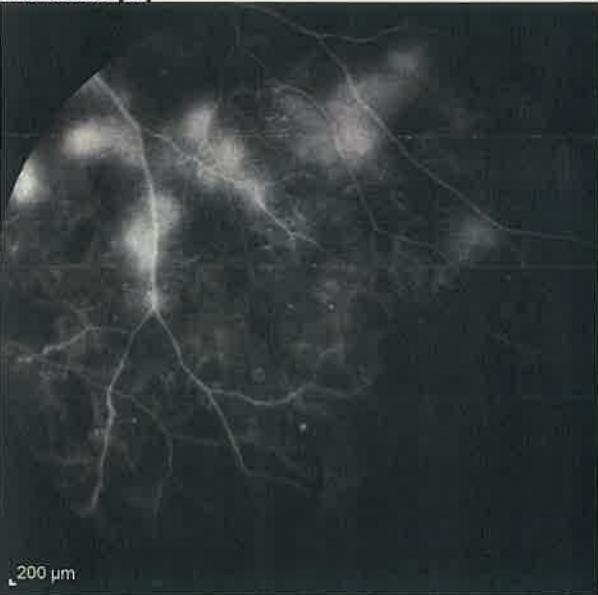FA 3:00.30 55° [HS]



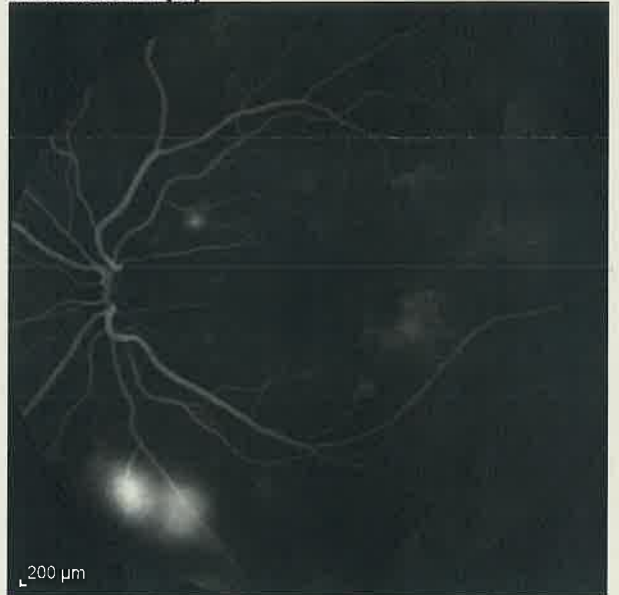FA 3:15.51 55° [HS]



FA 3:28.44 55° [HS]



FA 4:50.93 55° ART [HS]





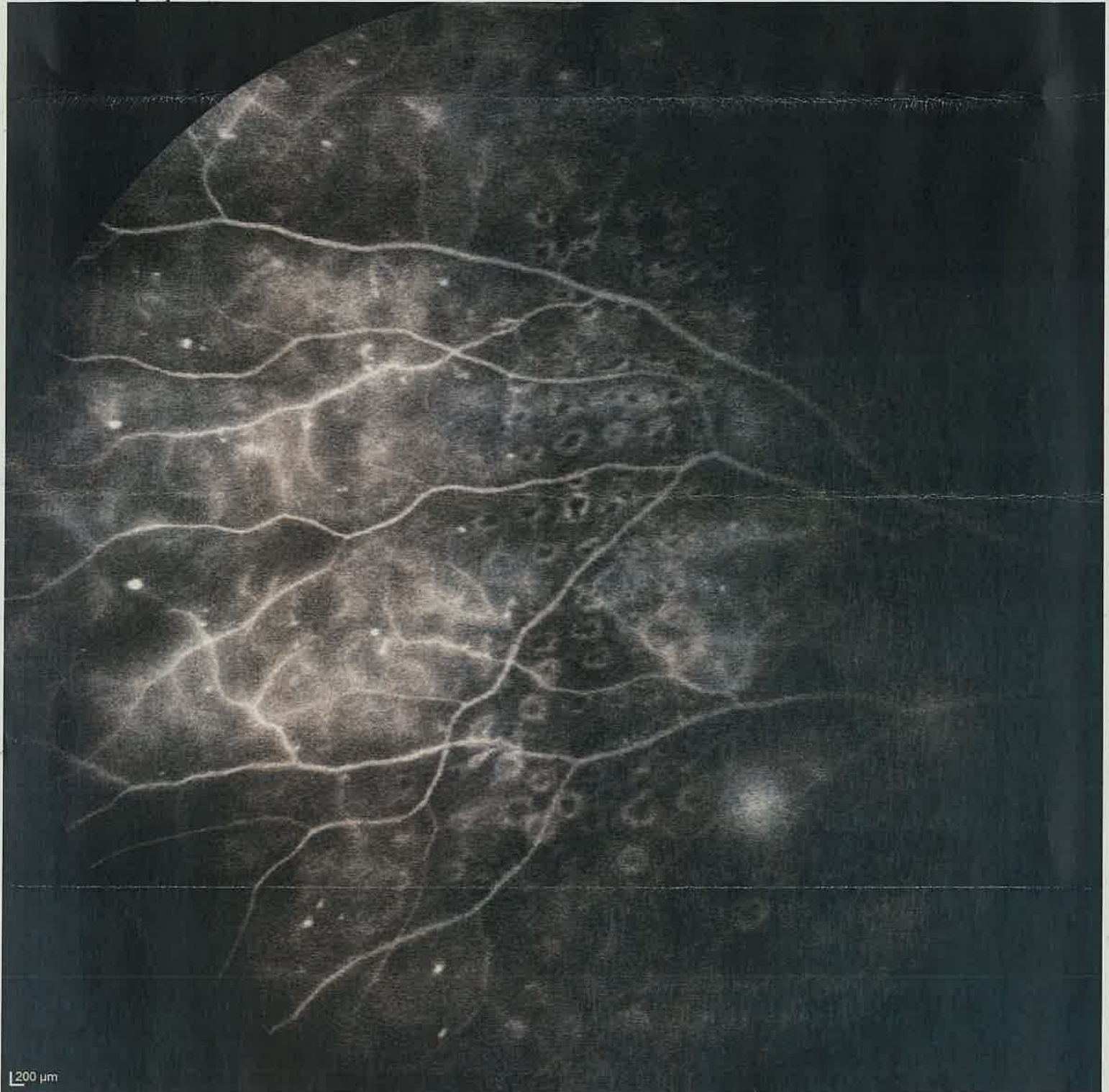Patient: **[REDACTED]**  
Patient ID: ---  
Diagnosis: ---

DOB: 16/mar/1994  
Exam.: 12/dic/2022  
Comment: ---

Sex: F

**OD**

FA 3:56.58 55° [HS]



**CONCORSO PUBBLICO PER TITOLI ED ESAMI PER LA COPERTURA DI N° 1 POSTO DI:  
DIRIGENTE MEDICO OFTALMOLOGIA**

PROVA PRATICA N. 3

*Roberto...*

CAMPO VISIVO - EMIANOPSIA.

*By the JH*

*Tommaso...*

*[Handwritten signature]*

*[Handwritten signature]*

*[Handwritten signature]*

PROVA

~~ESCRITTA~~

*BR*

26/3/23

*Mi M. JH DM.*

Nome: \_\_\_\_\_ ID: \_\_\_\_\_ D.N.: ~~20220917~~

30-2 ZETA Fast

Mira di fissazione: centrale  
errori Sguardo: ---

Stimolo: III, Bianco  
Sfondo: W:31.5 ASB  
Strategia: ZETA Fast

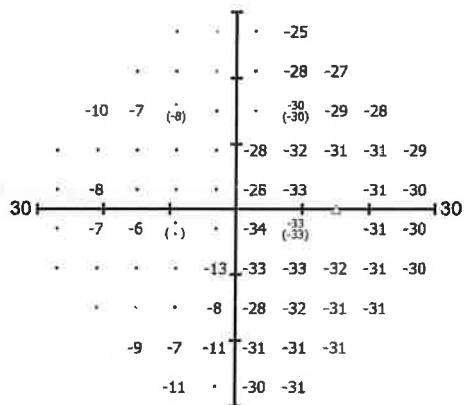

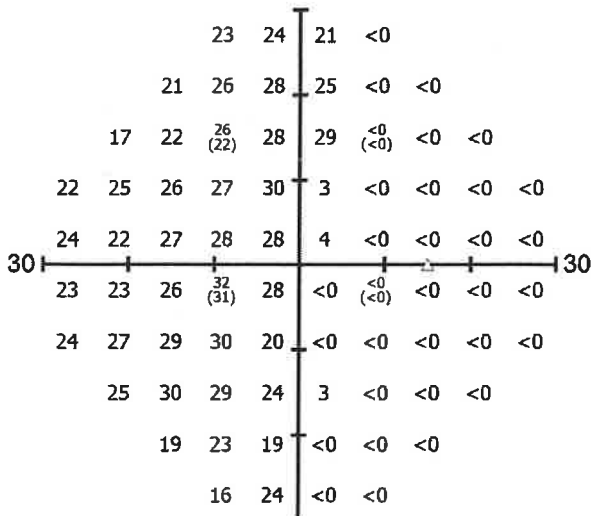
Diam. pupil.: 3,9 mm  
Rx usata:+6,00 DS +0,00 DC x 000°

Data: 27/09/2022  
Tempo: 14:20:47  
Età: 75

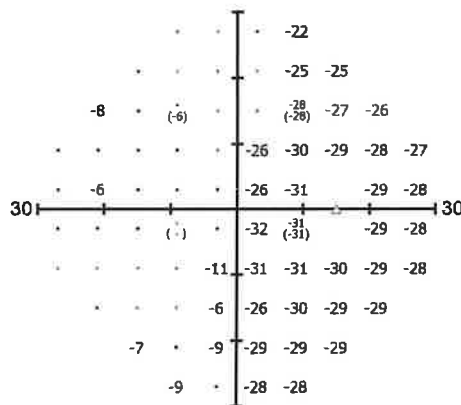
HK: 0/8  
FPOS: 0/8  
FNEG: 1/7

Durata: 04:43

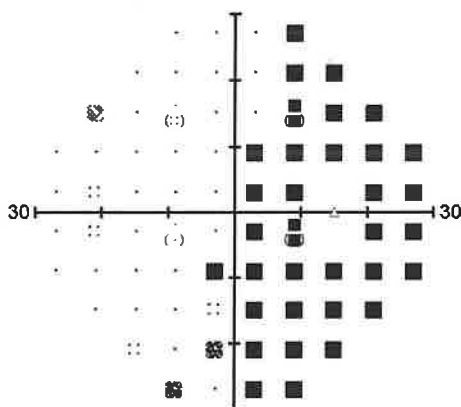
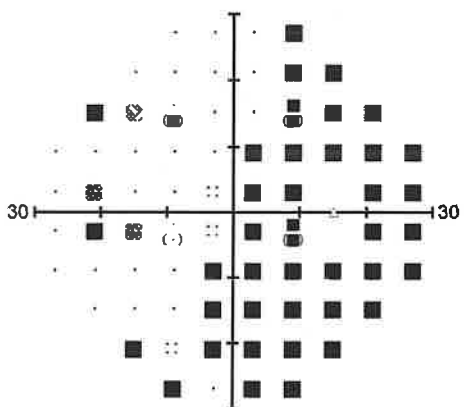

Risultati: ---



Total Deviation



Pattern Deviation



GHT:  
Oltre i limiti normali

VQi: 49,87%

MDh: -16,48 dB  
PSD: 13,87 dB

CPSD: 13,78 dB  
SFh: 1,48 dB  
MS: 13,48 dB



Commenti esame: \_\_\_\_\_



S.O.C. Oculistica  
Direttore Prof. Mauro Fioretto  
Ospedale "Santo Spirito" di Casale Monferrato  
ASL AL  
Segreteria 0142 434447 ore pomeridiane  
Ortottica 0142 434026 ore pomeridiane

Operatore:  
Utilizzatore:  
Dispositivo: PTS 2000:7700516;FW:20180913;SW:3.6.0.17  
Copyright 2023 Optopal Technology  
PTS ver.3.7.0.14



Nome:   
 ID:

D.N.: ~~XXXXXXXXXX~~

30-2 ZETA Fast

Mira di fissazione: centrale  
 errori Sguardo: ---

Stimolo: III, Bianco  
 Sfondo: W:31.5 ASB  
 Strategia: ZETA Fast

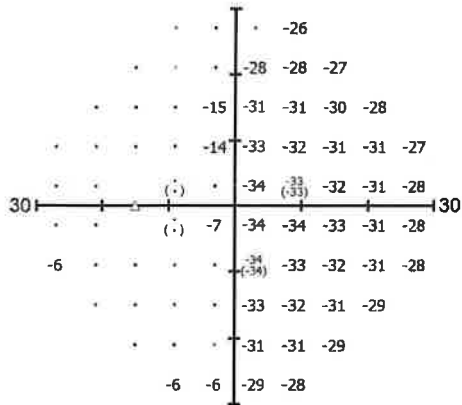

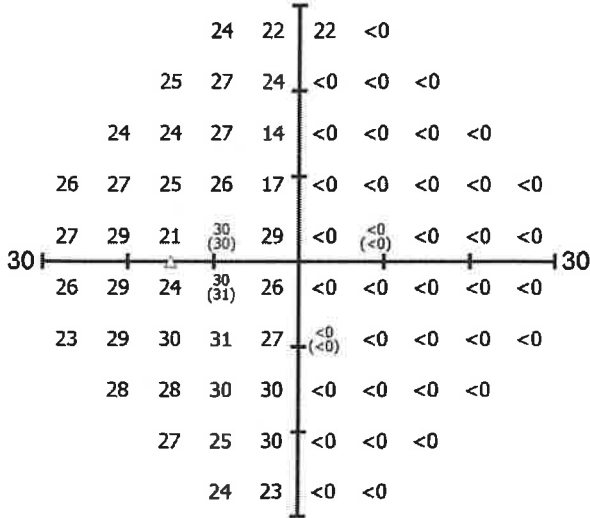
Diam. pupil.: 4,6 mm  
 Rx usata: +7,00 DS +0,00 DC x 000°

Data: 27/09/2022  
 Tempo: 14:26:27  
 Età: 75

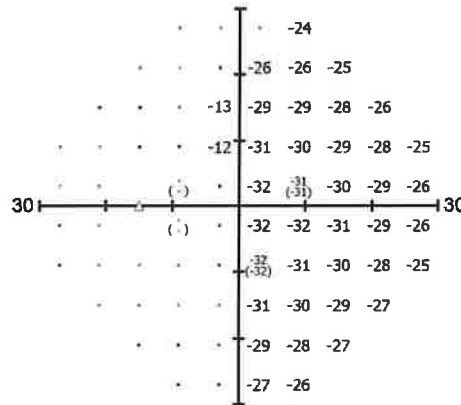
HK: 0/7  
 FPOS: 0/7  
 FNEG: 0/5

Durata: 04:26

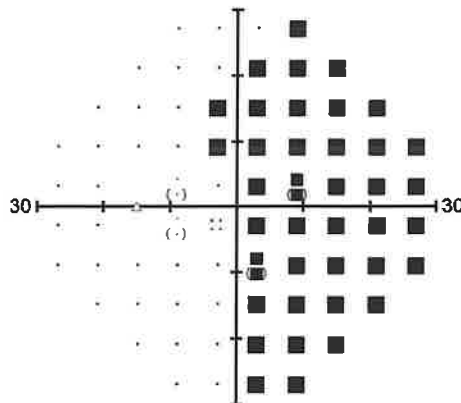
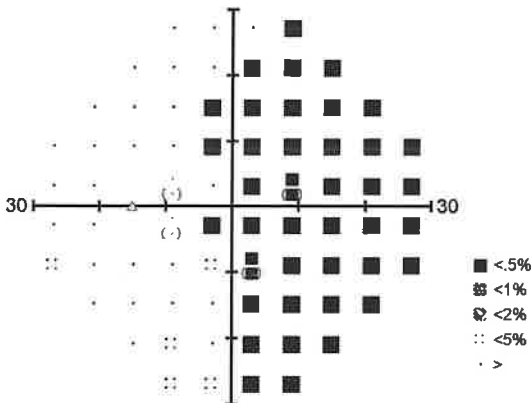

Risultati: ---



Total Deviation



Pattern Deviation



GHT:  
 Oltre i limiti normali

VQi: 45,96%

MDh: -18,09 dB  
 PSD: 14,76 dB

CPSD: 14,76 dB  
 SFh: 0,38 dB  
 MS: 12,55 dB

Commenti esame:



S.O.C. Oculistica  
 Direttore Prof. Mauro Fioretto  
 Ospedale "Santo Spirito" di Casale Monferrato  
 ASL AL  
 Segreteria 0142 434447 ore pomeridiane  
 Ortottica 0142 434026 ore pomeridiane

Operatore:  
 Utilizzatore:

Dispositivo: PTS 2000:7700516;FW:20180913;SW:3.6.0.17  
 Copyright 2023 Optopol Technology  
 PTS ver.3.7.0.14